

An unconventional remedy to an unstable, infected total hip prosthesis with pelvic discontinuity.

Keith Tamboowalla*, William Marley, Adeel Aqil, Sunil Panchani, Nikhil Shah
Lower limb unit, Wrightington hospital

Introduction

- Revision total hip replacement (THR) in the presence of local complications is challenging, with outcomes typically worse than those following primary THR.¹
- This is particularly true during a COVID-19 pandemic surge, when the risks of a major surgery often outweigh the benefits.
- We present a patient with a multiply revised THR who presented to us with a combination of infection, ARMD, recurrent dislocation, and pelvic discontinuity, treated in our unit.

Case presentation

A 68-year-old-lady, with a history of polymyalgia rheumatica, previous spine surgery and bilateral foot drop, was referred to our unit with an unstable right THR, which was multiply revised elsewhere for recurrent dislocations. Details of the index surgery were not available as these were performed overseas.

Imaging revealed a failed acetabular socket with type 3 B Paprosky bone loss (fig. 1) and a large walled off collection suggestive of ARMD (fig. 2- asterisk). Inflammatory markers and white cell counts were within normal limits.

She was planned for a complex revision THR.

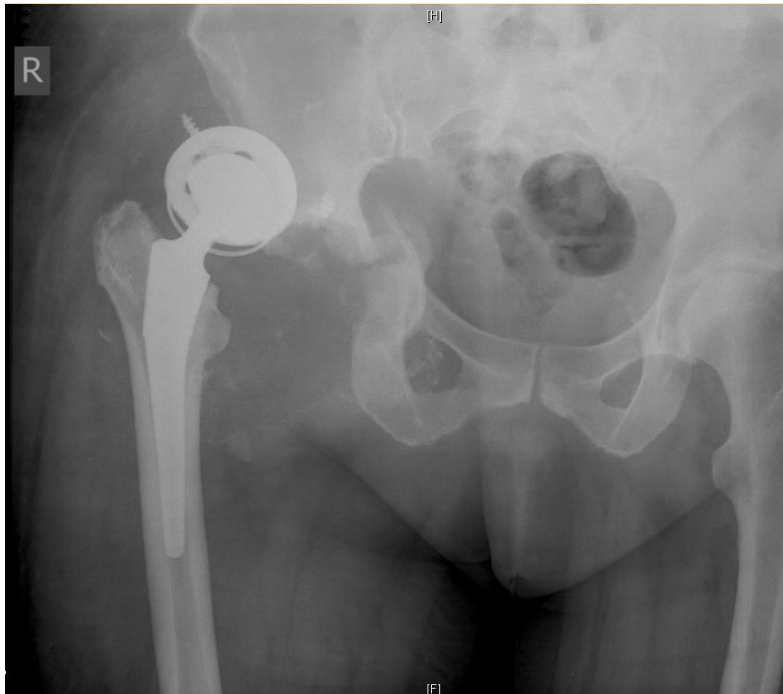

Fig. 1

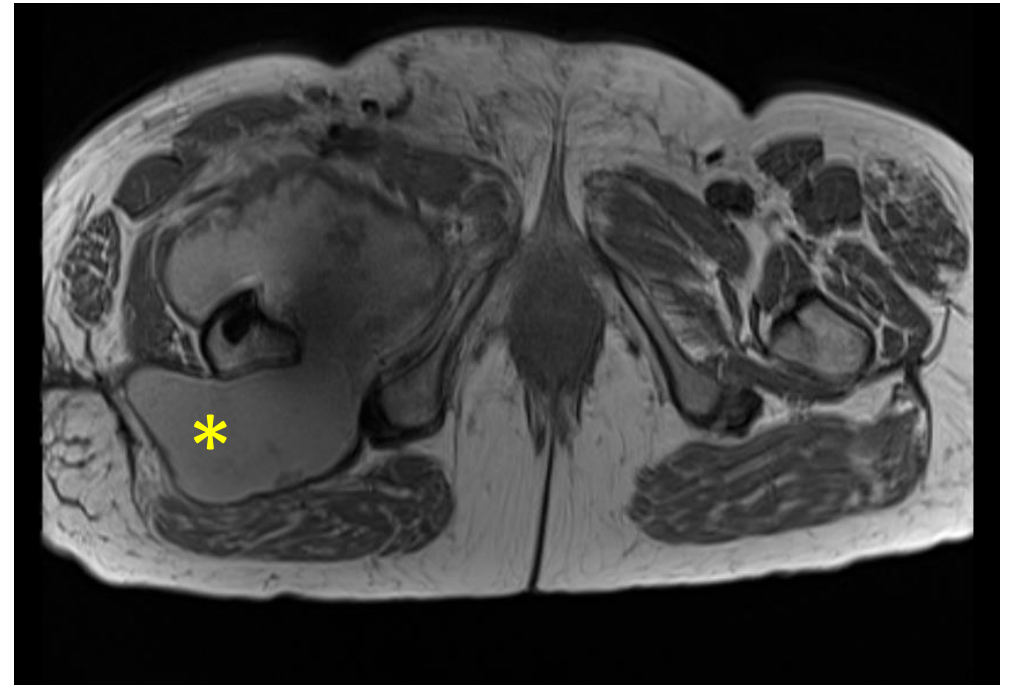


Fig. 2

Surgery 1: Open reduction & internal fixation of pelvic discontinuity + impaction bone grafting + porous titanium buttress reconstruction + revision of acetabular component

Intra-op findings suggestive of ARMD. Index surgery was likely metal-on-metal articulation.

Components: No damage on trunnion, femur stem showed solid ingrowth → hence stem retained. With the stably fixed discontinuity, and absence of obvious infection, a dual mobility socket was cemented in with a 28 mm ceramic head and a head neck adaptor. Intra-op cultures negative.

6 weeks after surgery 1

Dislocated right hip while bending forwards in a chair.
Underwent closed reduction → stable hip.
No further dislocations.

7 months after surgery 1

Developed **two sinuses** over operative scar, discharging frank pus - during 1st wave of COVID-19 pandemic. Risk of major surgery during pandemic → hence, managed with suppressive antibiotics.² Girdlestone arthroplasty was contemplated at this juncture.

Radiographs showed united pelvic discontinuity without loosening of prosthesis at 1 year (Fig. 3).

Paradoxically, hip pain improved. Given the pain from shoulders and knees (h/o polymyalgia rheumatica), the patient became keener to retain her hip rather than have it excised.

Surgery 2: DAIR procedure performed 15 months after surgery 1- to reduce the microbial load, keeping in mind the patient's functional requirements.

Outcome: At six months following surgery 2, the patient was mobilising pain-free with two crutches. The sinuses had healed up and there was no active discharge. Radiographs continued to show well fixed components and a well consolidated pelvis (Fig. 4).

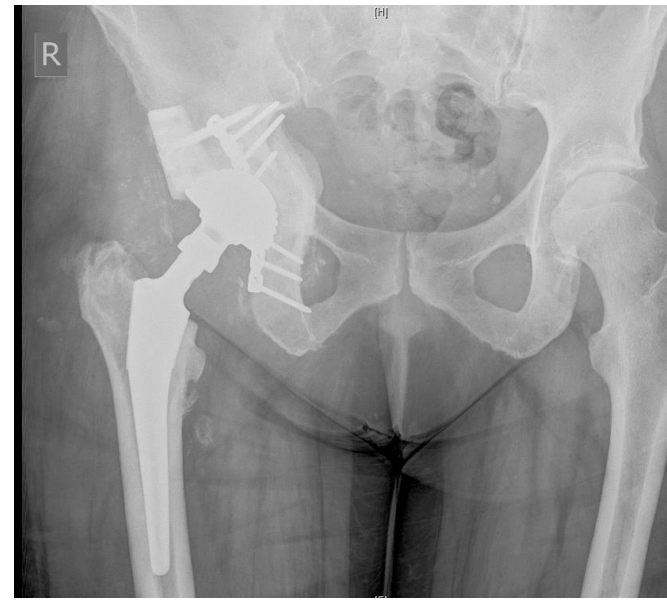


Fig. 3 showing a consolidated pelvic discontinuity and well-fixed prosthesis at 1 year post-surgery 1.

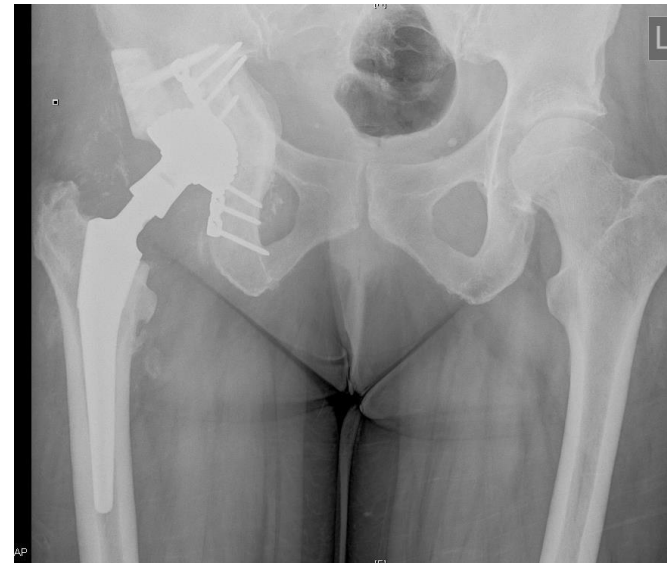

Fig. 4

Discussion: Fracture union in the presence of infection is rare. In our case, union of pelvic discontinuity occurred, in the presence of a stable osteosynthesis construct³ and suppressive antibiotics.

Chronic PJI's are best treated with removal of implants and reconstruction, often in a staged approach.⁴ However, given the risks associated with major revision surgery during the COVID-19 pandemic and the patient's functional needs, a DAIR procedure was performed as an unconventional solution,⁵ though literature suggests varying success rates between 28-62%⁶ with DAIR.

Conclusion: Fracture site stability is crucial for bony union, especially in the presence of infection. Although a staged revision remains the gold standard in treating chronic PJI's, DAIR might offer an unorthodox option, if the clinical situation demands it, in the presence of a stable functioning prosthesis.

3. Rightmire E, Zurakowski D, Vrahas M. Acute Infections After Fracture Repair. *Clin Orthop Relat Res.* 2008 Feb;466(2):466–72.

4. Cooper HJ, Della Valle CJ. The two-stage standard in revision total hip replacement. *Bone Joint J.* 2013 Nov 1;95-B(11):84–7.

5. Gardner J, Gioe TJ, Tatman P. Can this prosthesis be saved? Implant salvage attempts in infected primary TKA. In: *Clinical Orthopaedics and Related Research.* Springer New York LLC; 2011. p. 970–6.

6. Qasim SN, Swann A, Ashford R. The DAIR (debridement, antibiotics and implant retention) procedure for infected total knee replacement –a literature review. *SICOT-J.* 2017 Jan 11;3:2.

Thank you!